

Renal Volumetry-based Prediction of the Presence of Accessory Renal Artery: Computed Tomographic Angiography-based Study with Clinical Implications on Renal Doppler

Syed Mohammad Danish Qaseem^{1*}, Anoop Singhal², Nitin P. Ghonge²

¹Department of Radiodiagnosis, J N Medical College, AMU, Aligarh, Uttar Pradesh, India, ²Department of Radiodiagnosis, Indraprastha Apollo Hospital, New Delhi, India

Abstract

Background: The objective was to validate the hypothesis and evaluate whether the presence or absence of accessory renal artery can be predicted on the basis of volumetric parameters of kidney and diameter of the main renal artery (mRA). **Methods:** This retrospective analysis was performed in a total of 60 kidneys in 30 patients, who had computed tomographic (CT) angiography. The kidneys were segregated into control and study groups depending on the absence or presence of accessory renal artery. The total renal volumes were measured using renal length, breadth, and height in mm³. The renal artery diameters were also measured in mm, in the poststomal segment. Renal volume/renal artery diameter (V/d) was measured for each kidney in two groups, and the difference in mean V/d values (in mm²) in two groups was measured for statistical significance. **Results:** The mean V/d value in the study group with presence of the accessory renal artery was found to be 23,444.7 mm² (range: 16,229.1–32,490.0). The V/d value in the control group with the absence of accessory renal artery was found to be 19,717.15 mm² (range: 13,704.6–28,000.0). The mean values in the two groups showed a statistically significant difference in the V/d with a P value of 0.001 ($P < 0.05$). **Conclusion:** The study suggests that the possibility of the presence of the accessory renal artery is directly proportional to the total renal volume and inversely proportional to the diameter of mRA. The use of integrated volumetric parameter (V/d) is therefore likely to play a key role in the prediction of the presence of accessory renal artery on imaging studies. Renal volumetry on CT angiography may help predict the presence of accessory renal artery and thus may have implications on renal Doppler studies.

Keywords: Accessory renal artery, computed tomographic angiography, renal volume

INTRODUCTION

Accessory renal arteries (aRA) are one of the commonly identified variants and are present in around 25% of people. Their detection is of significance where surgery is being contemplated before donor renal transplantation^[1,2] and also before interventional procedures like renal artery embolization.^[3] The term extra renal artery may be classified into the aberrant renal artery, supplying the renal poles or accessory renal artery, and supplying the renal hilum.^[4] aRA may be noted on both sides in around 10%–15% of cases. A solitary renal artery is seen in 70% of people. Double renal arteries may be seen in approximately 20% of people. Multiple renal arteries were first described by Eustachius in 1552.^[5] It has also been suggested that aRA may be related to hypertension in a few

people. Three-dimensional (3D) computed tomographic (CT) angiography is a fast, noninvasive modality for the evaluation of the renal arteries and its variations.

Our study was based on the hypothesis that the possibility of the presence of the accessory renal artery is directly proportional to the total renal volume and inversely proportional to the diameter of the main renal artery (mRA). This study is primarily aimed to validate this hypothesis and evaluate whether the presence or absence of accessory renal artery can be predicted on the basis of volumetric parameters of the kidney and the diameter of the mRA.

Address for correspondence: Dr. Syed Mohammad Danish Qaseem, Mansoor Manzil, Jamia Urdu Road, Aligarh, Uttar Pradesh, India. E-mail: danish_qaseem@rediffmail.com

Received: 15-01-2020 Revised: 07-04-2020 Accepted: 22-05-2020 Available Online: 24-08-2020

Access this article online

Quick Response Code:



Website:
www.jmuonline.org

DOI:
10.4103/JMU.JMU_6_20

This is an open access journal, and articles are distributed under the terms of the Creative Commons Attribution-NonCommercial-ShareAlike 4.0 License, which allows others to remix, tweak, and build upon the work non-commercially, as long as appropriate credit is given and the new creations are licensed under the identical terms.

For reprints contact: WKHLRPMedknow_reprints@wolterskluwer.com

How to cite this article: Qaseem SM, Singhal A, Ghonge NP. Renal volumetry-based prediction of the presence of accessory renal artery: Computed tomographic angiography-based study with clinical implications on renal doppler. J Med Ultrasound 2021;29:22-5.

MATERIALS AND METHODS

The study was carried out after obtaining approval from Indraprastha Apollo Hospital ethics committee. Informed consent was obtained from all the patients undergoing this study. The study was carried out retrospectively over 30 patients (60 kidneys), who were referred for 3D CT angiography for pretransplant assessment of donor patients. The patients that were included in the study ranged from 20 to 50 years. All the patients who had hypertension, diabetes, renal artery stenosis, and chronic kidney disease were excluded from the study, so as to remove the confounding factors which may affect the kidney size. The multidetector CT scanner which was used for the study was Toshiba Aquilion 64-slice scanner (Tokyo, Japan). The patient was given water orally as a negative contrast agent. Contrast material was injected at 3–4 ml/s for a volume of 120–150 ml a large-bore (18-G) intravenous line placed in the antecubital fossa. The postprocessing was done using GE-Centricity Picture Archiving and Communications Systems using Osirix 64-bit workstation. Once conventional CT data were obtained, 3D rendering tools like maximum intensity projection were utilized to produce the images that revealed exquisite anatomical renal vascular details.

All the patients included in the study were assessed on CT angiography for the presence or absence of the accessory renal artery. All patients with accessory renal artery constituted the study group, while patients with no accessory renal artery on CT angiography comprised the control group. The study variables included the presence or absence of accessory renal artery, renal volume, the maximum diameter of postostial renal artery segment in millimeters (mm), and the ratio of renal volume and renal artery diameter for each kidney (volume/renal artery diameter [V/d]) in both groups. The renal volume [Figure 1a and b] was determined by multiplying width (W in mm), length (L in mm), and height (H in mm), and the final value was divided by 2. The renal artery diameter was measured at a distance of 1–1.5 cm from the ostium, where the renal artery appears more uniform in caliber. If there was early-branching from the renal artery (which is any branch within 2.0 cm from the aorta), the caliber was measured before the level of branching. In patients who had a solitary renal artery, this artery was accepted as mRA, while in patients who had multiple renal arteries, the largest one was

accepted as mRA [Figure 2]. The difference in mean V/d values in the two groups was evaluated for statistical significance. Mann–Whitney statistical tests were used for the assessment of statistical validity.

RESULTS

This retrospective analysis was performed in a total of 60 kidneys in 30 patients, who had CT angiography as a part of the prerenal transplantation living-donor evaluation. The kidneys were segregated into two groups depending on whether the accessory renal artery was present or not. The total renal volumes and the renal artery diameters were measured. Renal V/d was measured for each kidney in two groups, and the difference in mean V/d values (in mm^2) in the two groups was measured for statistical significance.

There were 44 kidneys in which there was no accessory renal artery supplying it (control group). There were 16 kidneys in which a single accessory renal artery was noted (study group). There was not a single kidney where two or three aRA were seen supplying it.

The mean V/d value [Figure 3] in the group with the presence of the accessory renal artery was found to be 23,444.7 mm^2 (range: 16,229.1–32,490.0). The mean V/d value in the group with absence of accessory renal artery was found to be 19,717.15 mm^2 (range: 13,704.6–28,000.0). Mann–Whitney statistical tests were used for the assessment of statistical validity. The values in the two groups showed a statistically significant difference in the V/d with a P value of 0.001 ($P < 0.05$).

DISCUSSION

Although several possible causes and pathogenesis for hypertension have been described, most of such cases are idiopathic (around 90%–95% of cases).^[6] Among the known causative factors, renal artery stenosis is one of the common causes of high blood pressure in a few people.^[6,7] aRA leading to hypertension has also been suggested as a causative

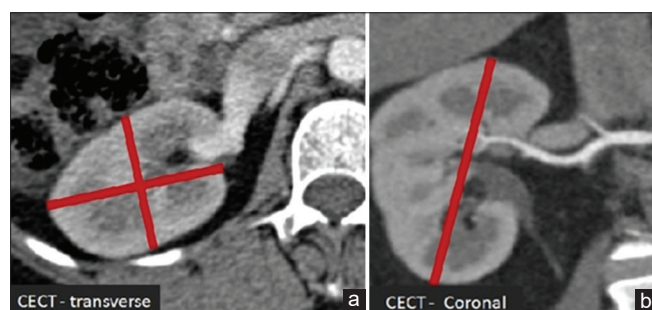


Figure 1: (a and b) Computed tomographic angiography coronal and transverse image showing the method of estimation of renal volume

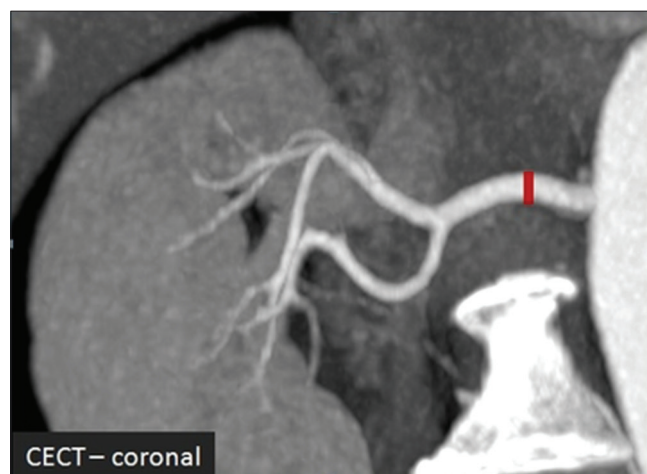


Figure 2: Computed tomographic angiography coronal image showing the method of measuring postostial segment of the main renal artery

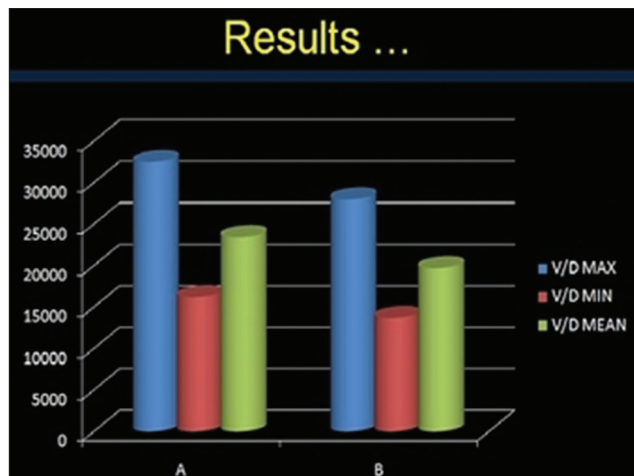


Figure 3: Showing the difference in mean volume/renal artery diameter value in the control and study groups

factor.^[7-12] This study thereby suggests the significance of the detection of the accessory renal artery.

Our study was based on the hypothesis that the possibility of the presence of the accessory renal artery is directly proportional to the total renal volume and inversely proportional to the diameter of mRA. The study primarily aimed to validate this hypothesis and evaluate whether the presence or absence of accessory renal artery can be predicted on the basis of volumetric parameters of the kidney and the diameter of the mRA on CT angiography. Prediction and detection of the accessory renal artery is important not only in the evaluation of hypertensive patients but also in the evaluation of living renal donors before surgery and renal artery embolization for various reasons. As to our knowledge, there have been very limited researches done in this area to explore and validate the relationship of renal volume and diameter of mRA with presence of the accessory renal artery.

3D volume-rendered CT angiography provides a fast, noninvasive modality for the evaluation of the renal vascular anatomy and common variants.

Aytac *et al.* carried out a study on ultrasound to evaluate whether the diameter of the mRA could be used to predict the presence of an accessory renal artery. Thus, they concluded that the presence of the mRA with a diameter smaller than usual in a kidney with normal dimensions can suggest the presence of an accessory renal artery in the sonographic examination.^[13]

Ramadan *et al.* also evaluated whether kidney size measurements and the mRA diameter can suggest anything about aRA. They inferred that the measurement of the mRA diameter and kidney length can provide a fairly good idea regarding the presence of an aRA.^[14]

In our study, the renal V/d was measured for each kidney in two groups, and the difference in mean V/d values (in mm^2) in the two groups was measured for statistical significance. The P value in the two groups showed a statistically significant difference in the V/d with P value of 0.001 ($P < 0.05$). The

results suggest that the possibility of the presence of the accessory renal artery is directly proportional to the total renal volume and inversely proportional to the diameter of mRA.

The study had its limitations. All patients who had hypertension, diabetes, and chronic kidney disease were excluded from the study, which could have affected the kidney size. These patients were excluded, as the aim of this study was merely to predict the presence of accessory renal artery based on the renal volume estimation and renal artery ostial diameters on 3D CT angiography. A wider spectrum of patients may be included in future studies to assess the same. The concept of this study may also be useful and applied in predicting the presence and diagnosing aRA on renal Dopplers, where aRAs are otherwise often missed. This may again be evaluated in future studies.

CONCLUSION

The stated study results suggest that the possibility of the presence of the accessory renal artery is directly proportional to the total renal volume and inversely proportional to the diameter of mRA. The use of combined volumetric parameter (V/d), therefore, may help in predicting the presence of accessory renal artery on imaging studies.

As the detection of the accessory renal artery is one of the most important limitations of the renal Doppler examination, renal volumetry-based prediction of the presence of the accessory renal artery is likely to increase the diagnostic accuracy of Doppler examination in clinical practice. This may be further validated on an Ultrasound Doppler-based prospective study.

Acknowledgments

We would like to thank the patients who contributed to the study.

Financial support and sponsorship

Nil.

Conflicts of interest

There are no conflicts of interest.

REFERENCES

- Urban BA, Ratner LE, Fishman EK. Three-dimensional volume-rendered CT angiography of the renal arteries and veins: Normal anatomy, variants, and clinical applications. *Radiographics* 2001;21:373-86.
- Sahani DV, Rastogi N, Greenfield AC, Kalva SP, Ko D, Saini S, *et al.* Multi-detector row CT in evaluation of 94 living renal donors by readers with varied experience. *Radiology* 2005;235:905-10.
- Varghese K, Adhyapak S. Therapeutic Embolization, Springer, Cham, Print ISBN978-3-319-42492-7 Online ISBN978-3-319-42494-1. DOI <https://doi.org/10.1007/978-3-319-42494-1>.
- Ozkan U, Oğuzkurt L, Tercan F, Kizilkiliç O, Koç Z, Koca N. Renal artery origins and variations: Angiographic evaluation of 855 consecutive patients. *Diagn Interv Radiol* 2006;12:183-6.
- Graves FT. The arterial anatomy of the congenitally abnormal kidney. *Br J Surg* 1969;56:533-41.
- Braunwald E, Isselbacher KJ, Wilson JD, Martin JB, Kasper D, Longo DL, *et al.* Harrison's Principles of Internal Medicine. 14th ed. New York, NY: McGraw-Hill; 1998. p. 1380-90.
- Bakker J, Beek FJ, Beutler JJ, Hene RJ, de Kort GA, de Lange EE, *et al.* Renal artery stenosis and accessory renal arteries: Accuracy of

- detection and visualization with gadolinium-enhanced breath-hold MR angiography. *Radiology* 1998;207:497-504.
8. Larsen W. *Human Embryology*. 1st ed. New York, NY: Churchill Livingstone; 1993. p. 235-53.
 9. Satyapal KS, Haffjee AA, Singh B, Ramsaroop L, Robbs JV, Kalideen JM. Additional renal arteries: Incidence and morphometry. *Surg Radiol Anat* 2001;23:33-8.
 10. Glodny B, Cromme S, Wörtler K, Winde G. A possible explanation for the frequent concomitance of arterial hypertension and multiple renal arteries. *Med Hypotheses* 2001;56:129-33.
 11. Marshall AG. Aberrant renal arteries and hypertension. *Lancet* 1951;2:701-5.
 12. Derrick JR, Tyson DR. The association of aberrant renal arteries and systemic hypertension. *Surgery* 1960;48:907-12.
 13. Aytac SK, Yigit H, Sancak T, Ozcan H. Correlation between the diameter of the main renal artery and the presence of an accessory renal artery: Sonographic and angiographic evaluation. *J Ultrasound Med* 2003;22:433-9.
 14. Ramadan SU, Yiğit H, Gökharman D, Tunçbilek I, Dolgun NA, Koşar P, *et al.* Can renal dimensions and the main renal artery diameter indicate the presence of an accessory renal artery? A 64-slice CT study. *Diagn Interv Radiol* 2011;17:266-71.